Tissue Repair, Regeneration and Wound Healing

Dr. Aso Ahmad Abdulla

Board Certified General and Laparoscopic Surgeon

FIBMS, MBChB

College of Medicine

University of Garmian

Tissue Repair

- **Repair, sometimes called healing, refers to the restoration of tissue architecture and function after an injury.**

  (By convention, the term *repair* is often used for parenchymal and connective tissues and *healing* for surface epithelia)

  Critical to the survival of an organism

  is the ability to repair the damage

  toxic insults and inflammation

  Hence, the inflammatory response to microbes and injured tissues not only serves to eliminate these dangers but also sets into motion the process of repair.
- **Repair of damaged tissues occurs by two types of reactions: regeneration by proliferation of residual (uninjured) cells and maturation of tissue stem cells**
- **deposition of connective tissue to form a scar.**

Responses after injury and Inflammation

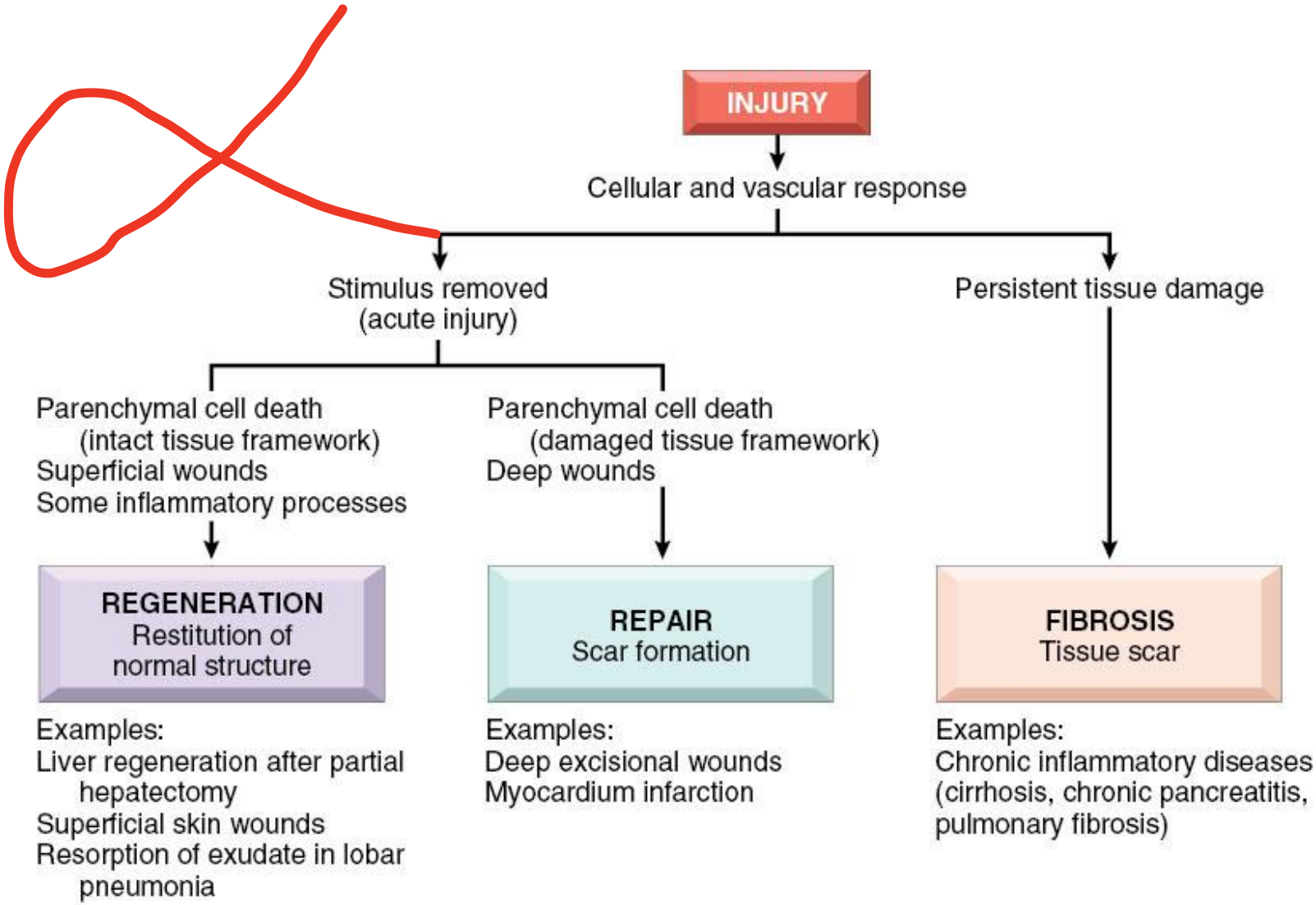

Copyright © 2010 by Saunders, an imprint of Elsevier Inc.

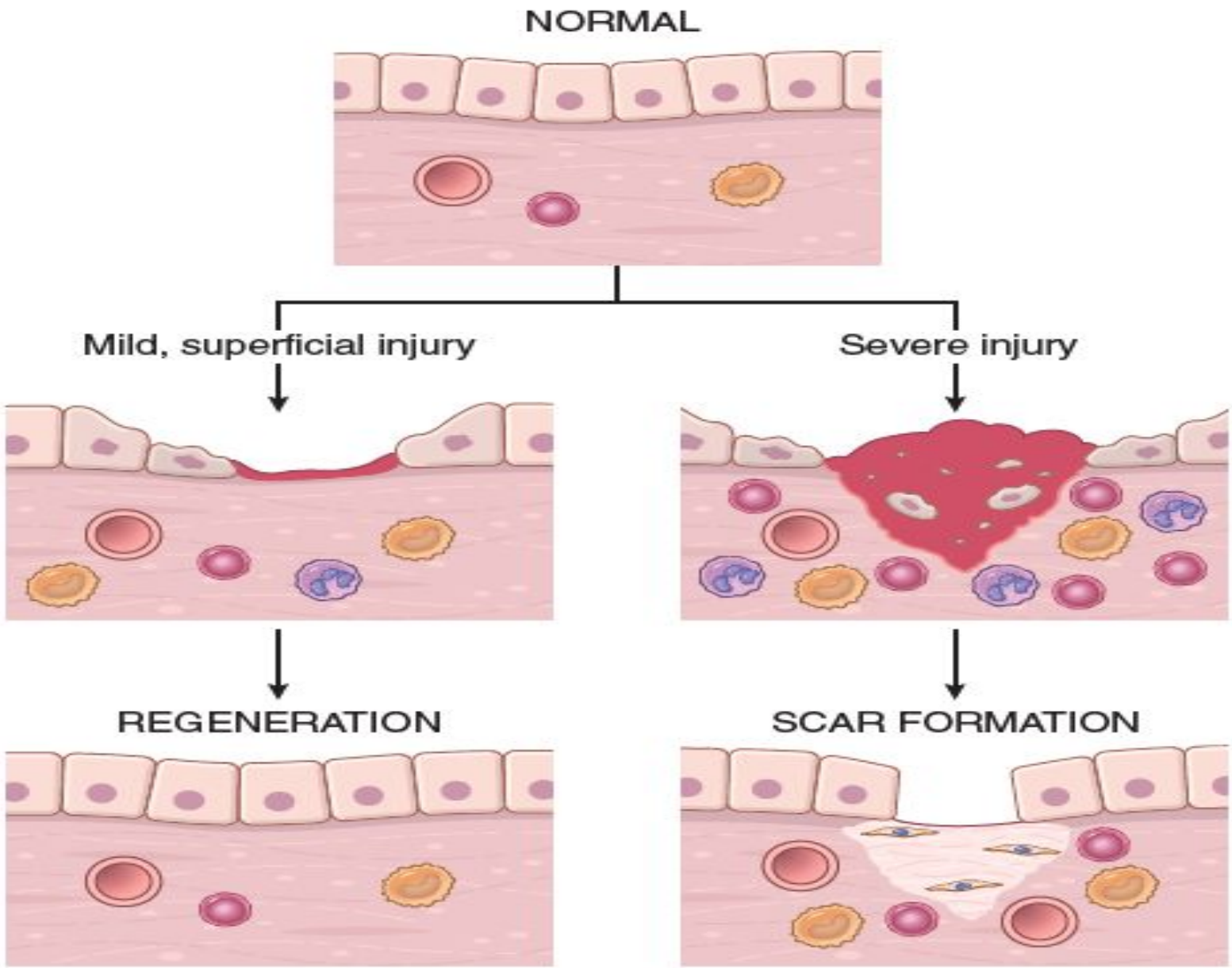

Fig. 3.23 Mechanisms of tissue repair: regeneration and scar formation. Following mild injury, which damages the epithelium but not the underlying tissue, resolution occurs by regeneration, but after more severe injury with damage to the connective tissue, repair is by scar formation.

- **Regeneration.** Some tissues are able to replace the damaged components and essentially return to a normal state; this process is called *regeneration*.
- Regeneration occurs by proliferation of cells
- that survive the injury
- retain the capacity to proliferate,
  - in the rapidly dividing epithelia of the skin and intestines, and in some parenchymal organs, notably the liver.
  - In other cases, tissue stem cells may contribute to the restoration of damaged tissues.
  - However, mammals have a limited capacity to regenerate damaged tissues and organs, and only some components of most tissues are able to fully restore themselves.

- **Connective tissue deposition (scar formation).** If the injured tissues are incapable of complete restitution, or if the supporting structures of the tissue are severely damaged, repair occurs by the laying down of connective (fibrous) tissue, a process that may result in scar formation.

  Although the fibrous scar is not normal, it provides enough structural stability that the injured tissue is usually able to function.

  The term *fibrosis* is most often used to describe the extensive deposition of collagen that occurs in the lungs, liver, kidney, and other organs as a consequence of chronic inflammation, or in the myocardium after extensive ischemic necrosis (infarction).

  If fibrosis develops in a tissue space occupied by an inflammatory exudate, it is called *organization* (as in organizing pneumonia affecting the lung)

Cell and Tissue Regeneration

- **The regeneration of injured cells and tissues involves cell proliferation, which is driven by growth factors and is critically dependent on the integrity of the extracellular matrix, and by the development of mature cells from stem cells.**

Cell Proliferation

- **Several cell types proliferate during tissue repair.**
  - include the remnants of the injured tissue (which attempt to restore normal structure),
  - vascular endothelial cells (to create new vessels that provide the nutrients needed for the repair process),
  - and fibroblasts (the source of the fibrous tissue that forms the scar to fill defects that cannot be corrected by regeneration).

- **Labile (continuously dividing) tissues.** Cells of these tissues are continuously being lost and replaced by maturation from tissue stem cells and by proliferation of mature cells.
- Labile cells include
  - hematopoietic cells in the bone marrow
  - the majority of surface epithelia,
  - such as the stratified squamous epithelia of the skin, oral cavity, vagina, and cervix; the cuboidal epithelia of the ducts draining exocrine organs (e.g., salivary glands, pancreas, biliary tract); the columnar epithelium of the gastrointestinal tract, uterus, and fallopian tubes; and the transitional epithelium of the urinary tract. These tissues can readily regenerate after injury as long as the pool of stem cells is preserved.

- **Stable tissues.** Cells of these tissues are quiescent (in the G_0 stage of the cell cycle) and have only minimal proliferative activity in their normal state.
- These cells are capable of dividing in response to injury or loss of tissue mass.
- Stable cells constitute the parenchyma of most solid tissues, such as liver, kidney, and pancreas.
- They also include endothelial cells, fibroblasts, and smooth muscle cells; the proliferation of these cells is particularly important in wound healing.
- With the exception of liver, stable tissues have a limited capacity to regenerate after injury.

- **Permanent tissues.** The cells of these tissues are considered to be terminally differentiated and non proliferative in postnatal life.
- The majority of neurons and cardiac muscle cells belong to this category.
- Thus, injury to the brain or heart is irreversible and results in a scar, because neurons and cardiac myocytes cannot regenerate.
- Limited stem cell replication and differentiation occur in some areas of the adult brain, and there is some evidence that heart muscle cells may proliferate after myocardial necrosis.
- Nevertheless, whatever proliferative capacity may exist in these tissues, it is insufficient to produce tissue regeneration after injury.
- Skeletal muscle is usually classified as a permanent tissue, but satellite cells attached to the endomysial sheath provide some regenerative capacity for muscle. In permanent tissues, repair is typically dominated by scar formation.

Important

Cell cycle

- The sequence of events that results in cell division
- is called the cell cycle. The cell cycle consists of G1 (presynthetic
- growth), S (DNA synthesis), G2 (premitotic
- growth), and M (mitotic) phases; quiescent cells that are
- not actively cycling are in the G0 state.

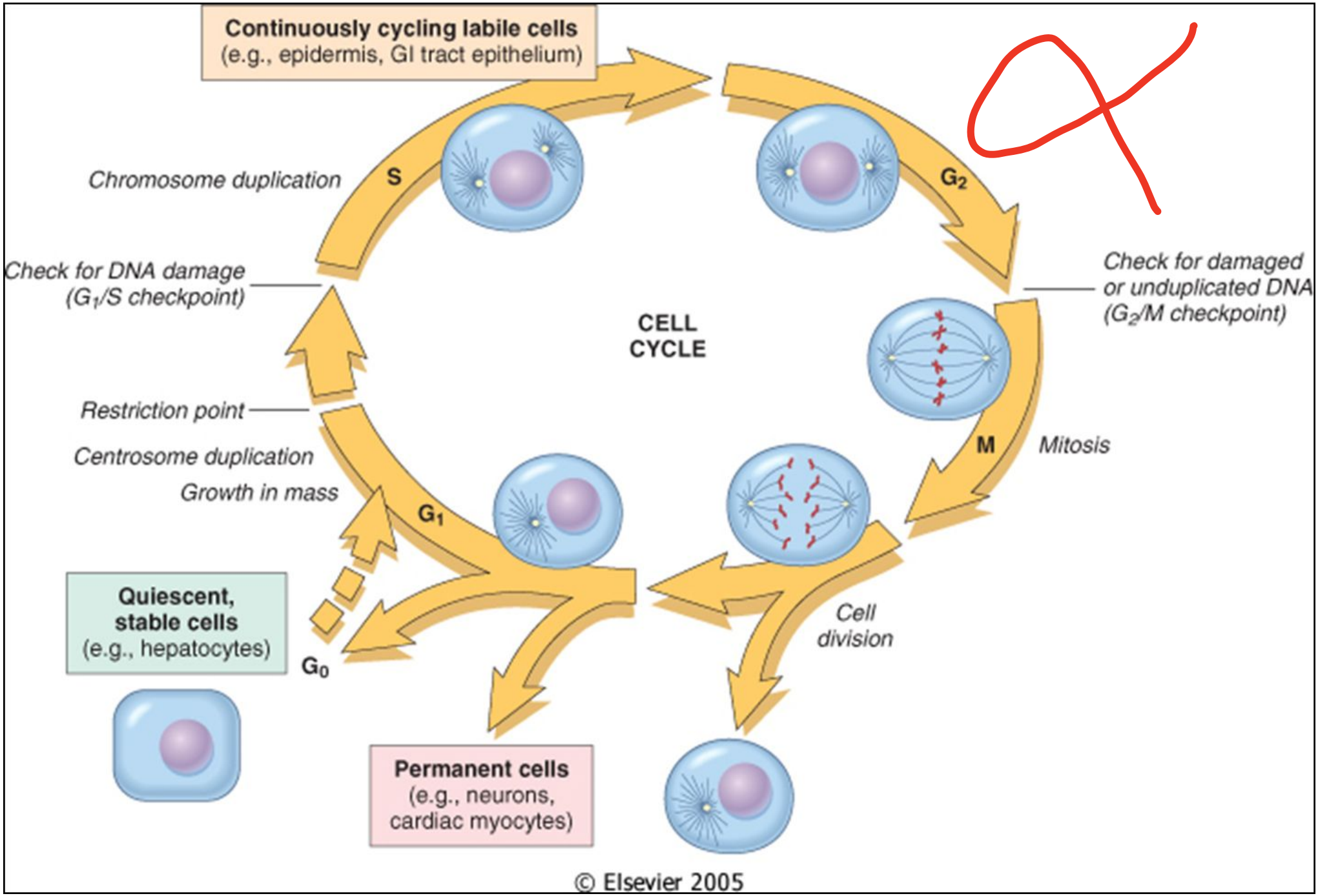
Continuously cycling labile cells
(e.g., epidermis, GI tract epithelium)
Chromosome duplication
S
G2
Check for DNA damage
(G1/S checkpoint)
Check for damaged
or unduplicated DNA
(G2/M checkpoint)
CELL
CYCLE
Restriction point
Centrosome duplication
Growth in mass
M
Mitosis
G1
Quiescent,
stable cells
(e.g., hepatocytes)
G0
Cell
division
Permanent cells
(e.g., neurons,
cardiac myocytes)
© Elsevier 2005

Mechanisms of Tissue Regeneration

- **In labile tissues**, such as the epithelia of the intestinal tract and skin, injured cells are rapidly replaced by proliferation of residual cells and differentiation of tissue stem cells provided the underlying basement membrane is intact.
- The growth factors involved in these processes are not defined.
- Loss of blood cells is corrected by proliferation of hematopoietic stem cells in the bone marrow and other tissues, driven by growth factors called colony-stimulating factors (CSFs), which are produced in response to the reduced numbers of blood cells.

- Tissue regeneration can occur in parenchymal organs with stable cell populations, but with the exception of the liver, this is usually a limited process.
- Pancreas, adrenal, thyroid, and lung have some regenerative capacity.
- Surgical removal of a kidney elicits in the remaining kidney a compensatory response that consists of both hypertrophy and hyperplasia of proximal duct cells.
- Mechanisms underlying this response are not understood, but likely involve local production of growth factors and interactions of cells with the ECM.
- Extraordinary capacity of the liver to regenerate has made it a valuable model for studying this process.

Liver Regeneration

- **Regeneration of the liver occurs by two major mechanisms:**
- ***Proliferation of remaining hepatocytes***
- ***Repopulation from progenitor cells.***

- **Proliferation of hepatocytes following partial hepatectomy.**
- In humans, resection of up to 90% of the liver can be corrected by proliferation of the residual hepatocytes.
- **Hepatocyte proliferation in the regenerating liver is triggered by the combined actions of cytokines and polypeptide growth factors.**

- In the first, or *priming*, phase, cytokines such as IL-6 are produced mainly by Kupffer cells and act on hepatocytes to make the parenchymal cells competent to receive and respond to growth factor signals.
- In the second, or *growth factor*, phase, growth factors such as HGF and TGF-α, produced by many cell types, act on primed hepatocytes to stimulate cell metabolism and entry of the cells into the cell cycle.
- Because hepatocytes are quiescent cells, it takes them several hours to enter the cell cycle, progress from G0 to G1, and reach the S phase of DNA replication.

- Almost all hepatocytes replicate during liver regeneration after partial hepatectomy. The wave of hepatocyte replication is followed by replication of nonparenchymal cells (Kupffer cells, endothelial cells, and stellate cells).

- During the phase of hepatocyte replication, more than 70 genes are activated; these include genes encoding transcription factors, cell cycle regulators, regulators of energy metabolism, and many others.

- In the final, *termination*, phase, hepatocytes return to quiescence.

Regeneration of Human Liver (living donor)

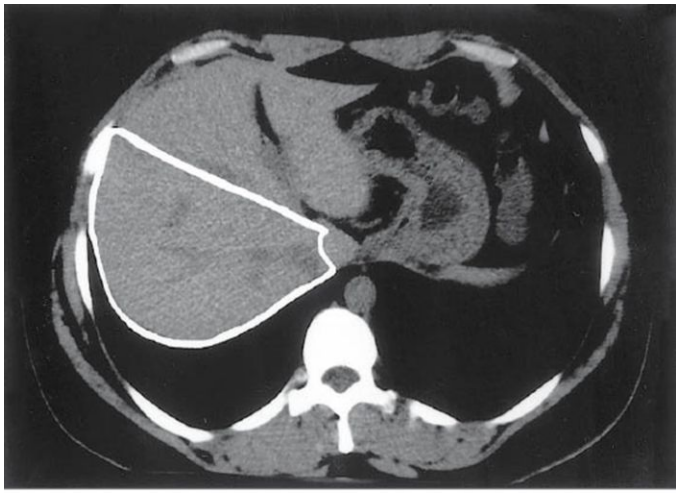

- Upper: CT scan before surgery, outlining portion of right lobe to be donated for transplantation

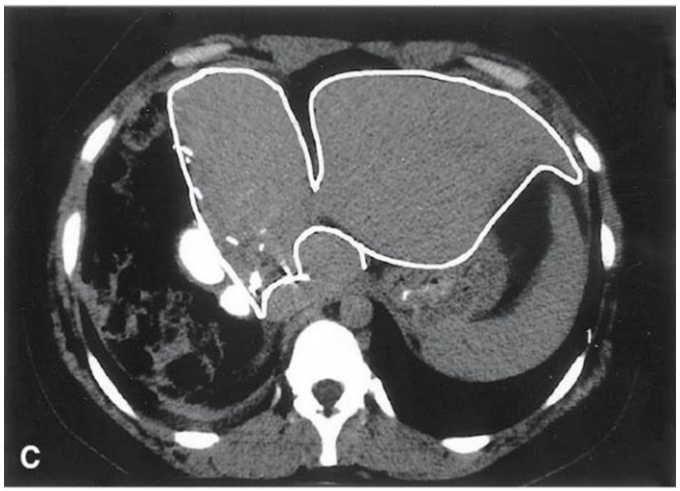

(Courtesy of R. Troisi, MD, Ghent University, Ghent, Belgium; reproduced in part from Fausto N: Liver regeneration. In Arias I, et al: The Liver: Biology and Pathobiology, 4th ed. Philadelphia, Lippincott Williams & Wilkins, 2001.)

- Lower: CT scan 1 week after partial hepatectomy; markedly enlarged left lobe due to compensatory hyperplasia (outlined); no regrowth of right lobe

Niche Cell



Niche cells are non-stem cells that “provide a sheltering environment that sequesters stem cells from differentiation stimuli, apoptotic stimuli, and other stimuli that would challenge stem cell reserves.”

Niche cells contribute to balance between adult stem cell quiescence and replication.

Niche Cells

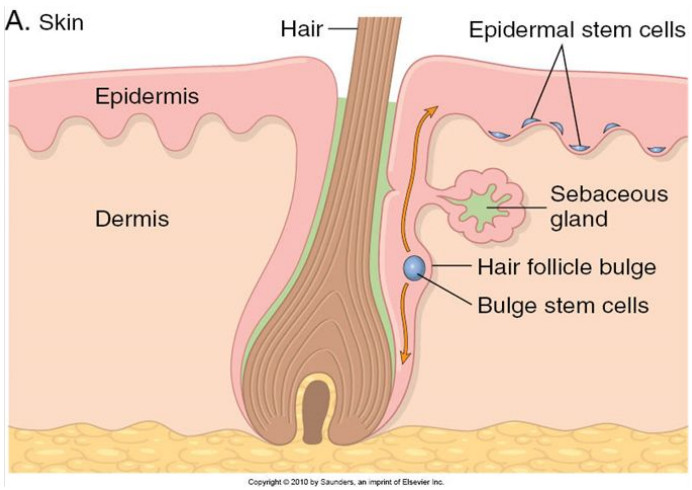

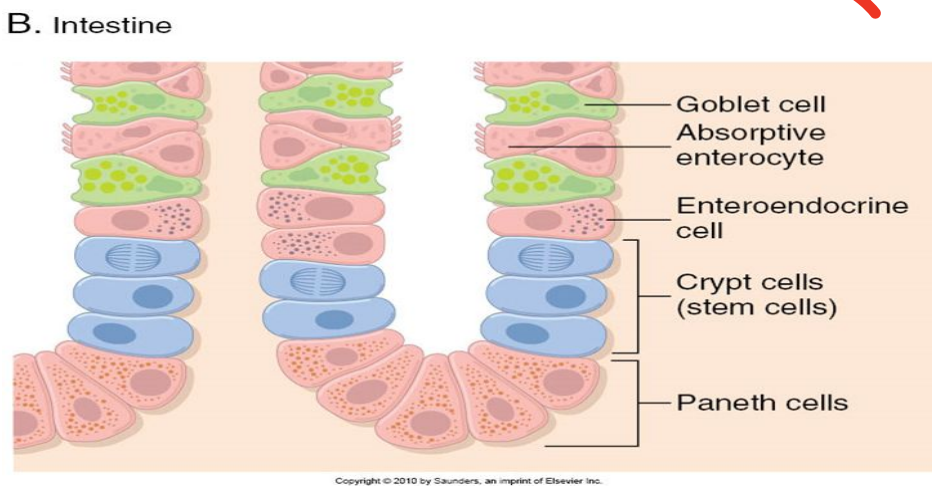

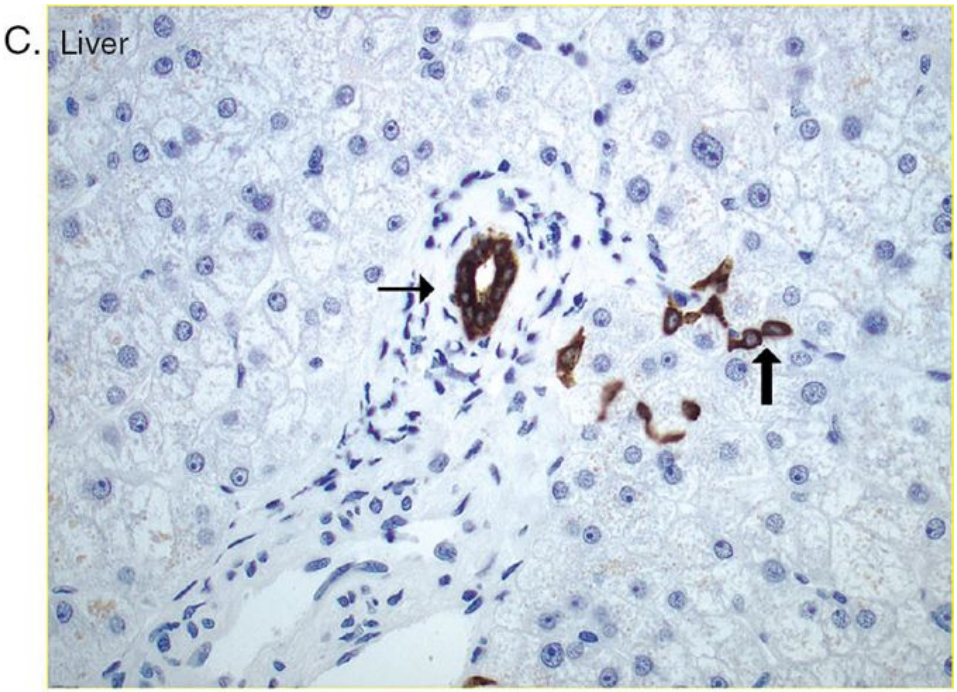

(Courtesy of Tania Roskams, MD, University of Leuven, Leuven, Belgium.)

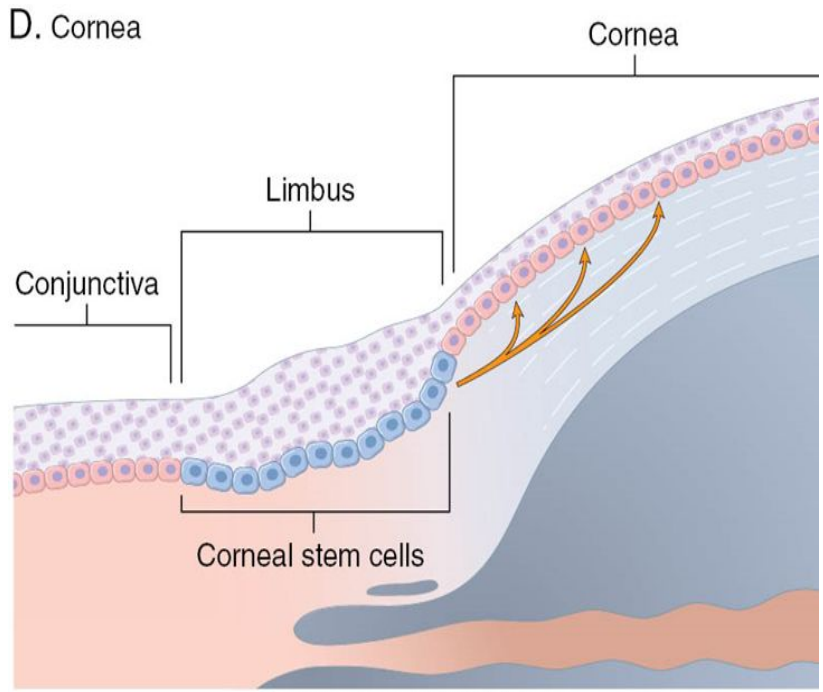

(Courtesy of T-T Sun, MD, New York University, New York, NY.)

Repair by Connective Tissue Deposition

- **If repair cannot be accomplished by regeneration alone**
  - **it occurs by replacement of the injured cells with connective tissue,**
    - **leading to the formation of a scar,**
    - **or by a combination of regeneration of some residual cells and scar formation.**

Steps in Scar Formation

- Repair by connective tissue deposition consists of sequential processes that follow tissue injury and the inflammatory response.
- **Angiogenesis** is the formation of new blood vessels, which supply nutrients and oxygen needed to support the repair process.
- Newly formed vessels are leaky because of incomplete interendothelial junctions and because VEGF, the growth factor that drives angiogenesis, increases vascular permeability.
- This leakiness accounts in part for the edema that may persist in healing wounds long after the acute inflammatory response has resolved.
- **Formation of granulation tissue.** Migration and proliferation of fibroblasts and deposition of loose connective tissue, together with the vessels and interspersed leukocytes, form *granulation tissue*.
- The **term *granulation tissue*** derives from its pink, soft, granular gross appearance, such as that seen beneath the scab of a skin wound.
- Its **histologic appearance** is characterized by proliferation of fibroblasts and new thin-walled, delicate capillaries (angiogenesis), in a loose extracellular matrix, often with admixed inflammatory cells, mainly macrophages. Granulation tissue progressively invades the site of injury; the amount of granulation tissue that is formed depends on the size of the tissue deficit created by the wound and the intensity of inflammation.

③ • **Remodeling of connective tissue.** Maturation and reorganization of the connective tissue (remodeling) produce the stable fibrous *scar*. The amount of connective tissue increases in the granulation tissue, eventually resulting in the formation of a scar, which may remodel over time.

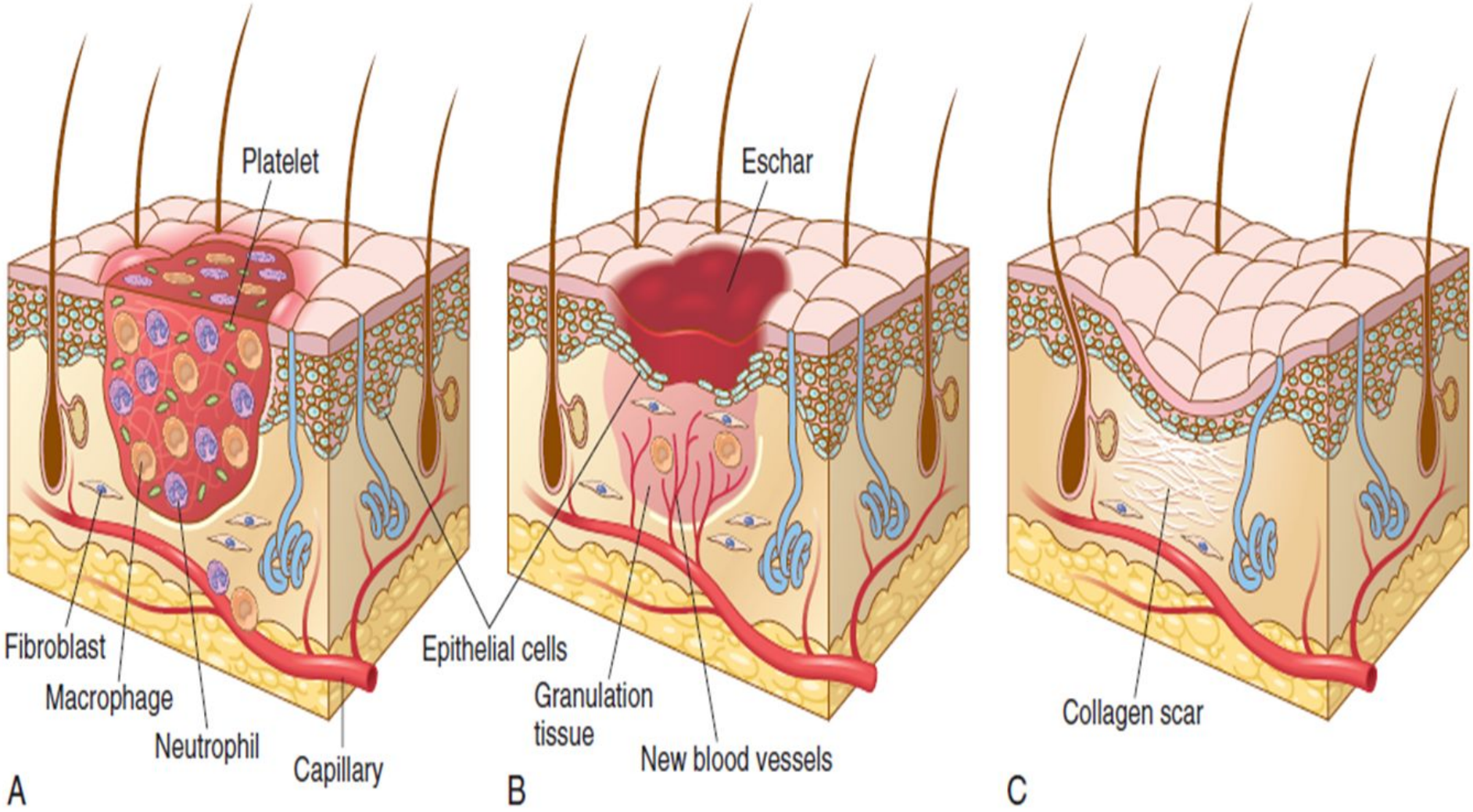

Fig. 3.24 Steps in repair by scar formation: healing of a large wound in the skin. This is an example of healing by second intention. (A) Hemostatic plug and inflammation. (B) Proliferation of epithelial cells; formation of granulation tissue by vessel growth and proliferating fibroblasts. (C) Remodeling to produce the fibrous scar.

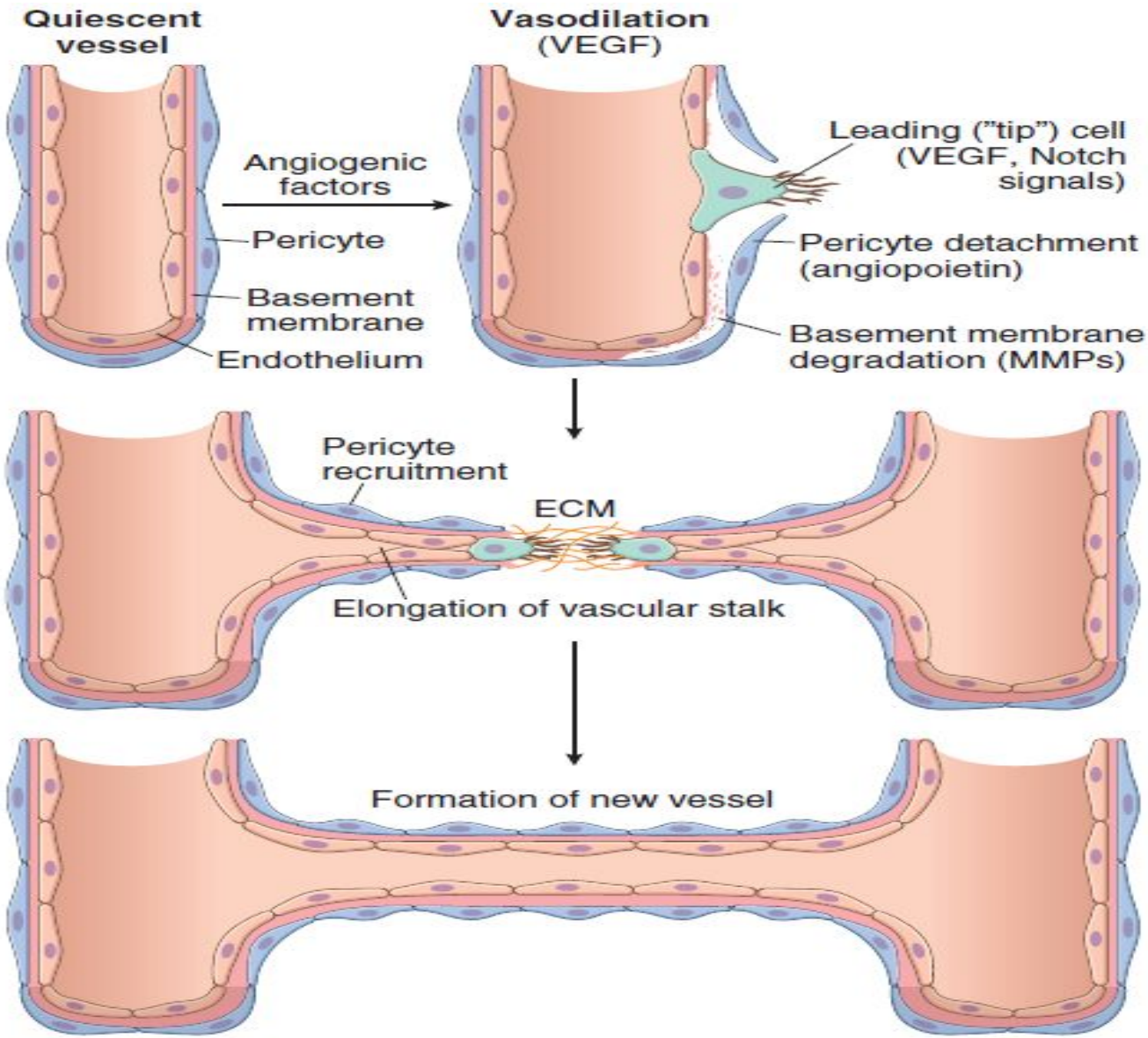

Fig. 3.25 Angiogenesis. In tissue repair, angiogenesis occurs mainly by the sprouting of new vessels. The steps in the process, and the major signals involved, are illustrated. The newly formed vessel joins up with other vessels (not shown) to form the new vascular bed.

Growth factors and ECM

A major role of growth factors is to stimulate the activity of proteins that are required for cell survival, growth and division.

The ECM is a network of interstitial proteins that constitutes a significant proportion of any tissue. Cell interactions with ECM are critical for development and healing, as well as for maintaining normal tissue architecture .

Much more than a simple “space filler” around cells, ECM serves several key functions:

ECM Functions

Mechanical support: anchors cells; medium for cell migration

Control of cell growth: regulate proliferation by ligands binding to surface integrin receptors

Modulation of cell differentiation: ECM proteins affect degree of differentiation via integrins

Storage of regulatory proteins: growth factors secreted & stored for response to injury and regeneration

Scaffolding for regeneration: organized tissue structure requires intact basement membranes

Injury to tissues capable of regeneration:normal structure restored only if ECM Is not disrupted

If ECM disrupted: collagen replaces normal cells (scar)

EXTRACELLULAR MATRIX –WOUND STRENGTH

- The wound is strengthened by proliferation of fibroblast and myofibroblast which get structural support from the extracellular matrix
- In addition ECM can direct cell migration ,attachment , differentiation and organization
- ECM has five main components

1)collagen

2)adhesive glycoprotein

fibronectin - plasma tissue

tenascin or cytotactin

thrombospondin

3) basement membrane

4)elastic fibres

- 5)proteoglycans
  - chondroitin sulphate
  - heparin sulphate
  - dermatin sulphate
  - keratin sulphate
  - hyaluronic acid

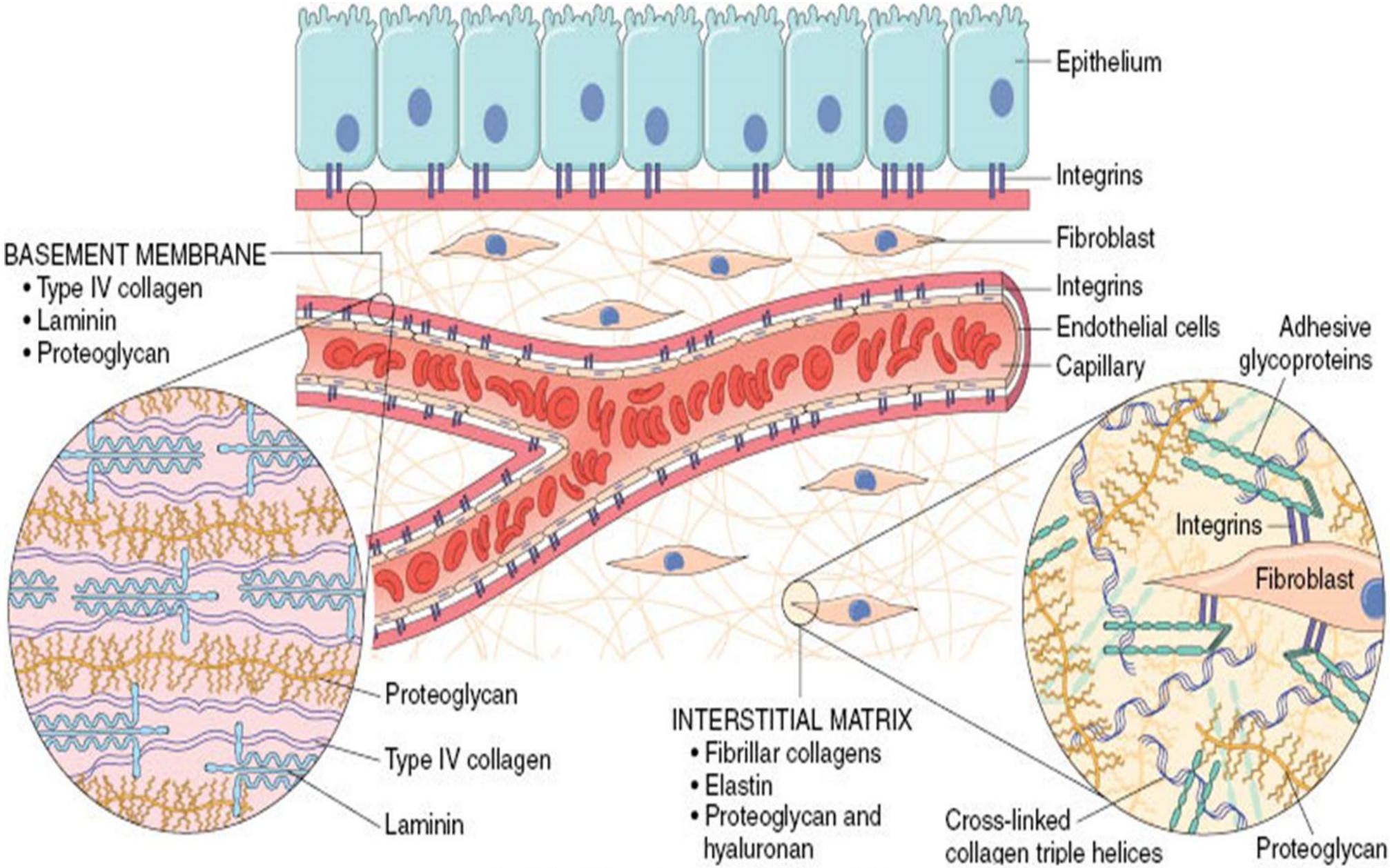

Copyright © 2010 by Saunders, an imprint of Elsevier Inc.

Granulation Tissue

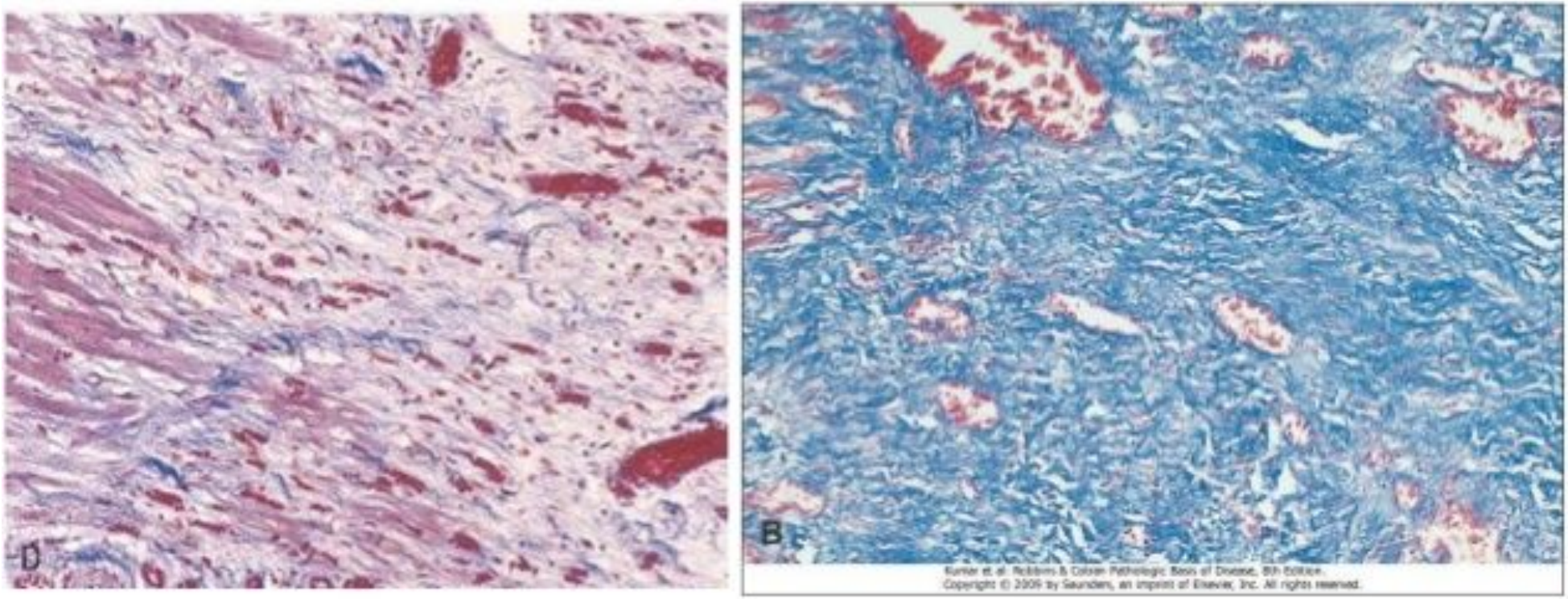

Granulation tissue showing numerous blood vessels, edema, and a loose extracellular matrix containing occasional inflammatory cells. Collagen is stained blue by the trichrome stain; minimal mature collagen can be seen at this point. **B,** Trichrome stain of mature scar, showing dense collagen, with only scattered vascular channels.

Healing of Skin Wounds

- Process that involves both epithelial regeneration and the formation of connective tissue scar and is thus illustrative of the general principles that apply to healing in all tissues.
- Based on the nature and size of the wound, the healing of skin wounds is said to occur by first or second intention.

Healing by First Intention (Primary Union)

- This is defined as healing of a wound which has the following
- characteristics:
- i) clean and uninfected;
- ii) surgically incised;
- iii) without much loss of cells and tissue; and
- iv) edges of wound are approximated by surgical sutures.

.

- 1. Initial haemorrhage. Immediately after injury, the space
- between the approximated surfaces of incised wound is filled
- with blood which then clots and seals the wound against
- dehydration and infection.
- 2. Acute inflammatory response. This occurs within 24
- hours with appearance of polymorphs from the margins of
- incision. By 3rd day, polymorphs are replaced by
- macrophages

.

- 3. Epithelial changes. The basal cells of epidermis from both
- the cut margins start proliferating and migrating towards incisional space in the form of epithelial spurs. A well approximated wound is covered by a **layer of epithelium in 48 hours**. The migrated epidermal cells separate the underlying viable dermis from the overlying necrotic material and clot, forming scab which is cast off. The basal cells from the margins continue to divide.
- **By 5th day**, a multilayered new epidermis is formed which is differentiated into superficial and deeper layers.
- 4. Organisation. **By 3rd day**, fibroblasts also invade the wound area. **By 5th day**, new collagen fibrils start forming which dominate till healing is completed. **In 4 weeks**, the scar tissue with scanty cellular and vascular elements, a few inflammatory cells and epithelialised surface is formed.

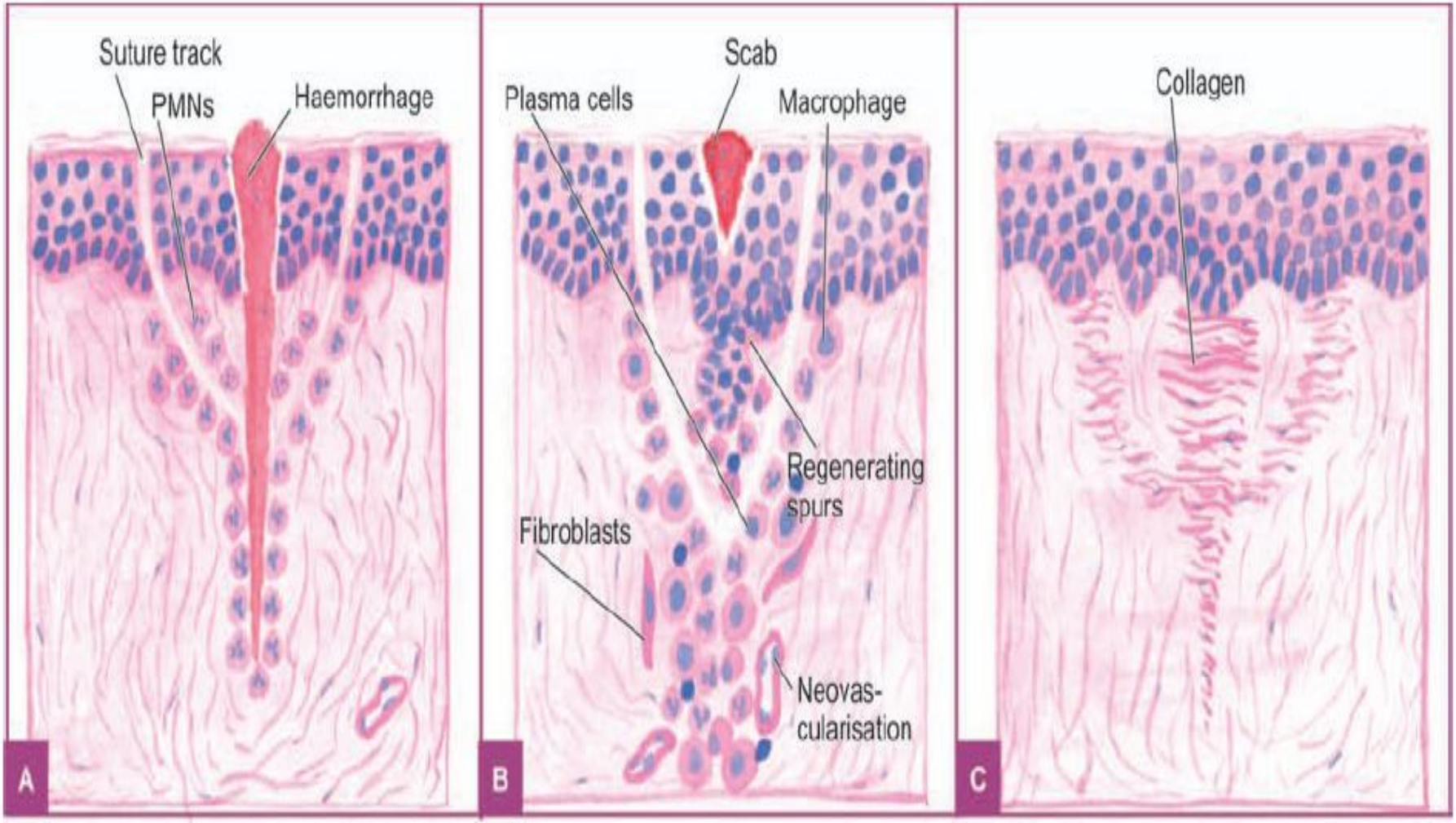

Figure 6.42 Primary union of skin wounds. A, The incised wound as well as suture track on either side are filled with blood clot and there is inflammatory response from the margins. B, Spurs of epidermal cells migrate along the incised margin on either side as well as around the suture track. Formation of granulation tissue also begins from below. C, Removal of suture at around 7th day results in scar tissue at the sites of incision and suture track.

Healing by Second Intention (Secondary Union)

This is defined as healing of a wound having the following characteristics:

i) open with a large tissue defect, at times infected;

ii) having extensive loss of cells and tissues; and

iii) the wound is not approximated by surgical sutures but is left open.

The basic events in secondary union are similar to primary union but differ in having a larger tissue defect which has to be bridged. Hence healing takes place from the base upwards as well as from the margins inwards. The healing by second intention is slow and results in a large, at times ugly, scar as compared to rapid healing and neat scar of primary union.

The sequence of events in secondary union is illustrated in Fig. 6.43 and described below:

•

1. Initial haemorrhage. As a result of injury, the wound space is filled with blood and fibrin clot which dries.

2. Inflammatory phase. There is an initial acute inflammatory response followed by appearance of macrophages which clear off the debris as in primary union.

3. Epithelial changes. As in primary healing, the epidermal cells from both the margins of wound proliferate and migrate into the wound in the form of epithelial spurs till they meet in the middle and re-epithelialise the gap completely.

However, the proliferating epithelial cells do not cover the surface fully until granulation tissue from base has started filling the wound space. In this way, pre-existing viable connective tissue is separated from necrotic material and clot on the surface, forming scab which is cast off. In time, the regenerated epidermis becomes stratified and keratinised.

4. Granulation tissue. Main bulk of secondary healing is by granulations. Granulation tissue is formed by proliferation of fibroblasts and neovascularisation from the adjoining viable elements. The newly-formed granulation tissue is deep red, granular and very fragile. With time, the scar on maturation becomes pale and white due to increase in collagen and decrease in vascularity.

5. Wound contraction. Contraction of wound is an important feature of secondary healing, not seen in primary healing. Due to the action of myofibroblasts present in granulation tissue, the wound contracts to one-third to onefourth of its original size. Wound contraction occurs at a time

when active granulation tissue is being formed.

6. Presence of infection. Bacterial contamination of an open wound delays the process of healing due to release of bacterial toxins that provoke necrosis, suppuration and thrombosis. Surgical removal of dead and necrosed tissue, debridement, helps in preventing the bacterial infection of open wounds.

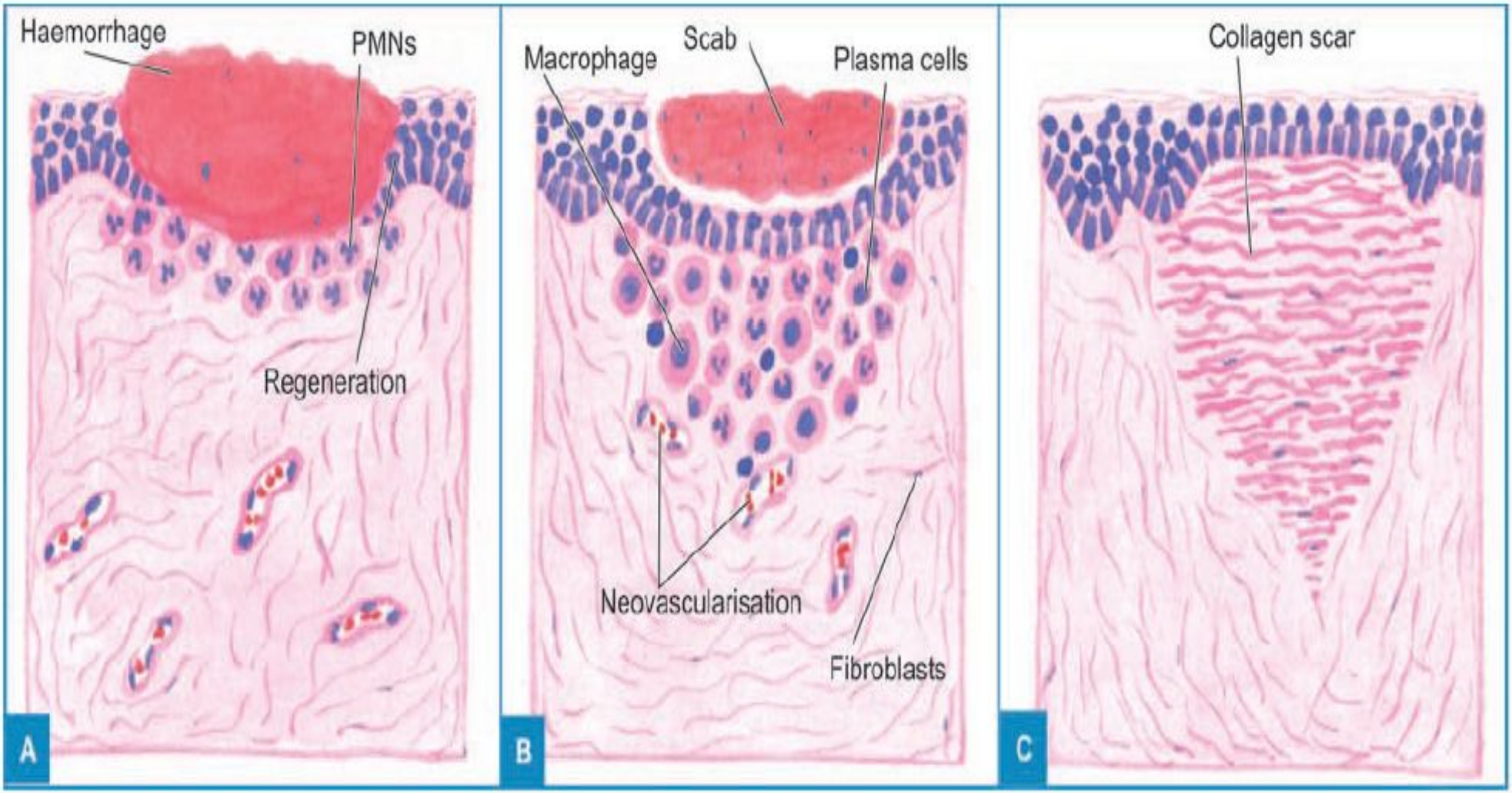

Figure 6.43 Secondary union of skin wounds. A, The open wound is filled with blood clot and there is inflammatory response at the junction of viable tissue. B, Epithelial spurs from the margins of wound meet in the middle to cover the gap and separate the underlying viable tissue from necrotic tissue at the surface forming scab. C, After contraction of the wound, a scar smaller than the original wound is left.

Fig. 3.27 Chronic wounds illustrating defects in wound healing. (A–D) External appearance of skin ulcers. *(From Eming SA, Margin P, Tomic-Canic M: Wound repair and regeneration: mechanisms, signaling, and translation,* Sci Transl Med *6:265, 2014.)* (A) Venous leg ulcer; (B) arterial ulcer, with more extensive tissue necrosis; (C) diabetic ulcer; and (D) pressure sore. (E–F) Histologic appearance of a diabetic ulcer. (E) ulcer crater; (F) chronic inflammation and granulation tissue.

زۆر گرنگ

TABLE 6.6: Differences between Primary and Secondary Union of Wounds.

Feature	Primary Union	Secondary Union
1. *Cleanliness of wound*	Clean	Unclean
2. *Infection*	Generally uninfected	May be infected
3. *Margins*	Surgical clean	Irregular
4. *Sutures*	Used	Not used
5. *Healing*	Scanty granulation tissue at the incised gap and along suture tracks	Exuberant granulation tissue to fill the gap
6. *Outcome*	Neat linear scar	Contracted irregular wound
7. *Complications*	Infrequent, epidermal inclusion cyst formation	Suppuration, may require debridement

COMPLICATIONS OF WOUND HEALING

- Infection of wound due to entry of bacteria delays the healing
- Stich abscess –infection of suture track
- Implantation (epidermal) cyst formation may occur due to persistence of epithelial cells in the wound after healing
- Pigmentation of healed wounds may at times may have rust like colour due to staining wih haemosiderin
- Deficient scar formation due to inadequate formation of granulation tissue
- Incisional hernia/wound dehisence a weak scar,especially after laprotomy may be the site of bursting open of a wound

- exuberant granulation/proud flesh Another deviation in wound healing is the formation of excessive amounts of granulation tissue, which protrudes above the level of the surrounding skin and in fact blocks re-epithelialization
- Hypertrophied scars and keloid formation at times scar formed is excessive ugly and painful.Excessive formation of collagen in healing may result in keloid (claw like) formation
- Excessive contraction exaggeration of wound contractures or cicatrisation
- Neoplasia rarely ,scar may be the site for development of carcinoma later eg : squamous cell carcinoma in marjolins ulcer i.e a scar formed following burns on skin

Factors That Impair Tissue Repair

Infection is one of the most important causes of delayed healing; it prolongs inflammation and potentially increases the local tissue injury.

- Diabetes is a metabolic disease that compromises tissue repair for many reasons and is an important systemic cause of abnormal wound healing.
- Nutritional status has profound effects on repair; protein malnutrition and vitamin C deficiency, for example, inhibit collagen synthesis and retard healing.
-

•

Glucocorticoids (steroids) have well-documented antiinflammatory effects, and their administration may result in weak scars because they inhibit TGF-β production and diminish fibrosis. In some instances, however, the anti-inflammatory effects of glucocorticoids are desirable. For example, in corneal infections, glucocorticoids may be prescribed (along with antibiotics) to reduce the likelihood of opacity due to collagen deposition

•

Mechanical factors such as increased local pressure or torsion may cause wounds to pull apart (dehisce).

- Poor perfusion, resulting either from arteriosclerosis and diabetes or from obstructed venous drainage (e.g., in varicose veins), also impairs healing.
- Foreign bodies such as fragments of steel, glass, or even bone impede healing.
- The type and extent of tissue injury affects the subsequent repair.

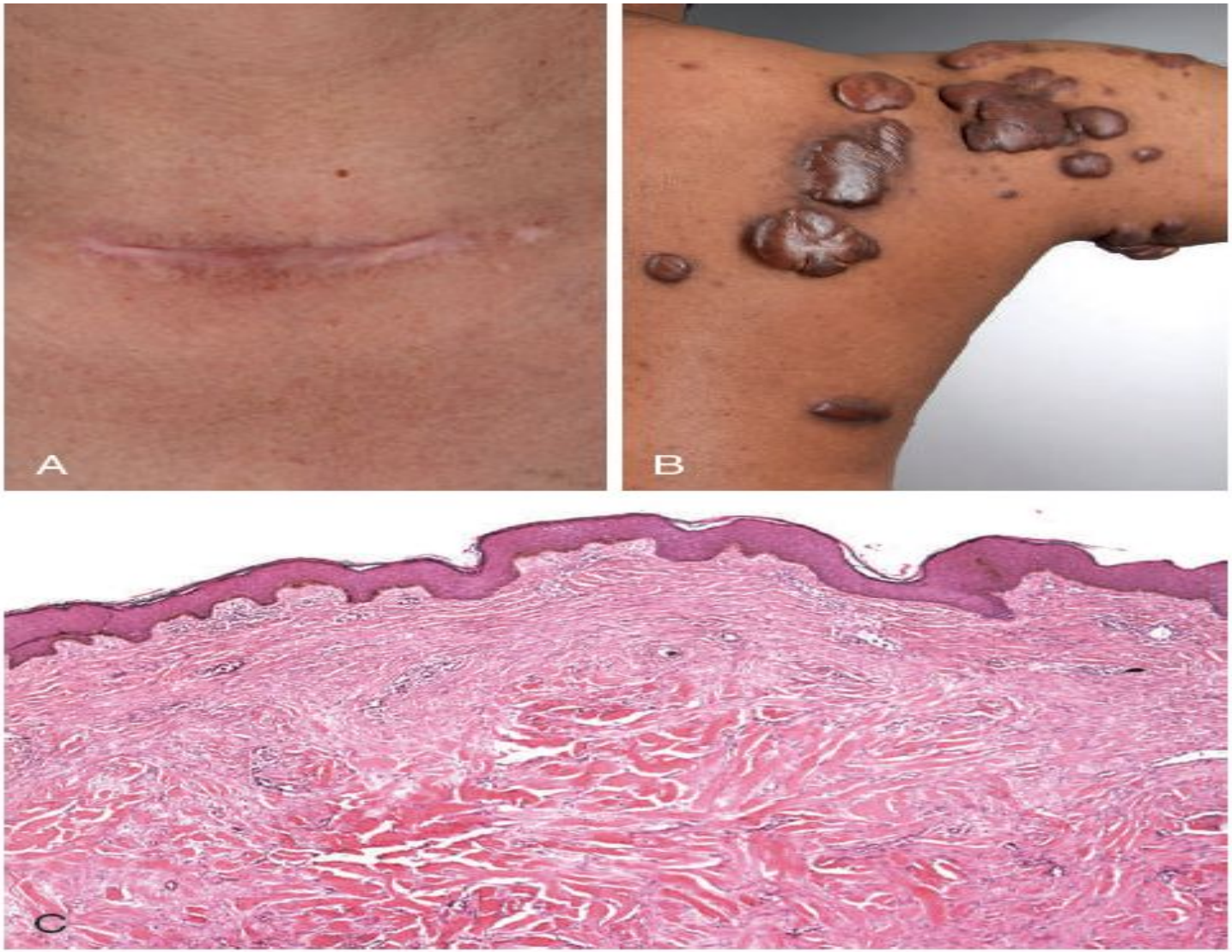

Fig. 3.28 Clinical examples of excessive scarring and collagen deposition. (A) Hypertrophic scar. (B) Keloid. (C) Microscopic appearance of a keloid. Note the thick connective tissue deposition in the dermis. *(A–B from Eming SA, Margin P, Tomic-Canic M: Wound repair and regeneration: mechanisms, signaling, and translation,* Sci Transl Med *6:265, 2014, p. 2.)*

Fibrosis in Parenchymal Organs

The term fibrosis is used to denote the excessive deposition of collagen and other ECM components in a tissue.

The terms scar and fibrosis may be used interchangeably, but fibrosis most often refers to the abnormal deposition of collagen that occurs in internal organs in chronic diseases. The basic mechanisms of fibrosis are the same as those of scar formation in the skin during tissue repair. Fibrosis is a pathologic process induced by persistent injurious stimuli such as chronic infections and immunologic reactions, and is typically associated with loss of tissue (Fig. 3.29). It may be responsible for substantial organ dysfunction and even organ failure.

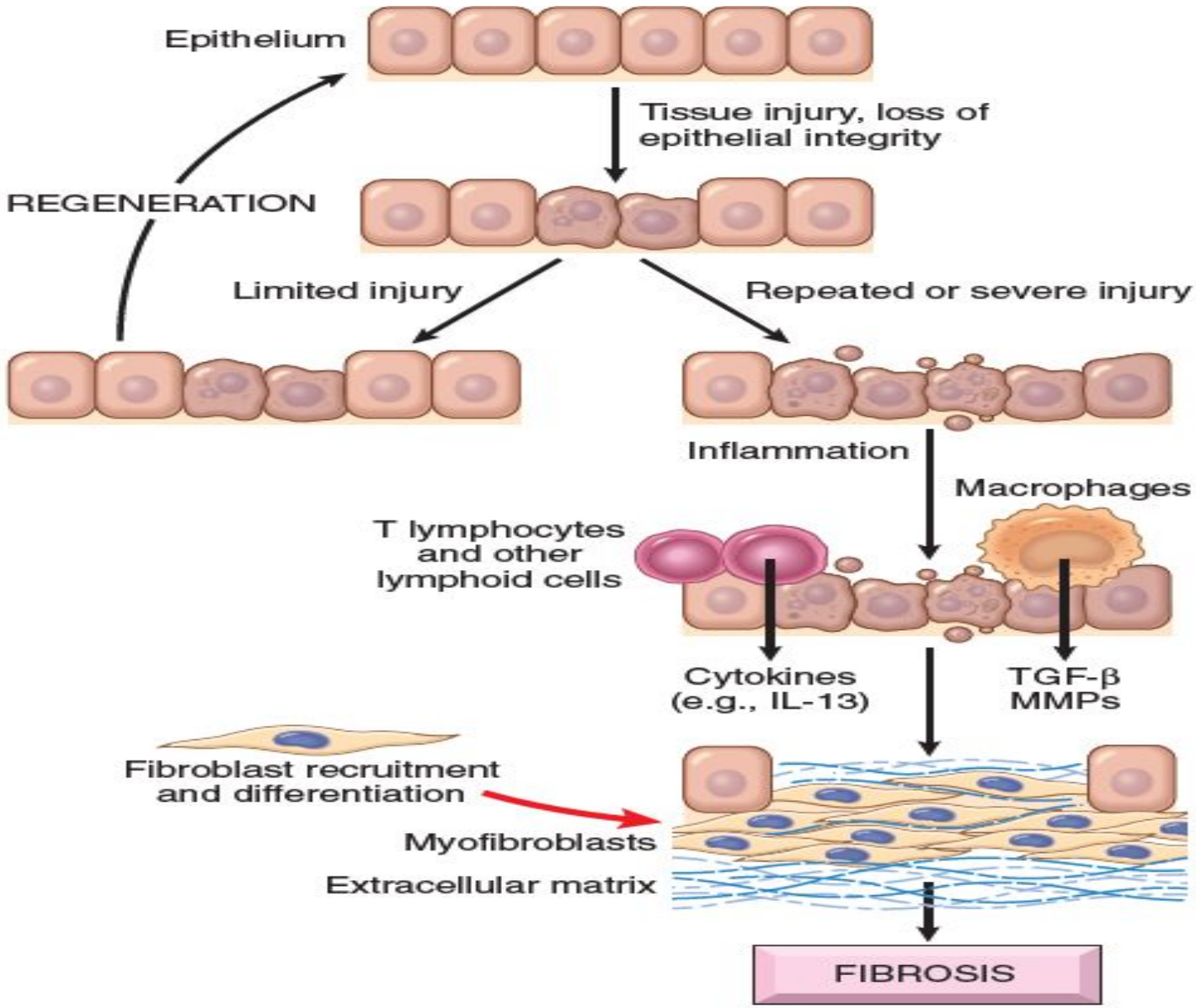

Fig. 3.29 Mechanisms of fibrosis. Persistent tissue injury leads to chronic inflammation and loss of tissue architecture. Cytokines produced by macrophages and other leukocytes stimulate the migration and proliferation of fibroblasts and myofibroblasts and the deposition of collagen and other extracellular matrix proteins. The net result is replacement of normal tissue by fibrosis.

As discussed earlier, the major cytokine involved in fibrosis is TGF-β. The mechanisms that lead to increased TGF-β activity in fibrosis are not precisely known, but cell death by necrosis or apoptosis and the production of ROS seem to be important triggers, regardless of the tissue. The cells that produce collagen in response to TGF-β stimulation may vary depending on the tissue. In most organs, such as in the lung and kidney, myofibroblasts are the main source of collagen, but stellate cells are the major collagen producers in liver cirrhosis.

fibrosis associated with chronic inflammation

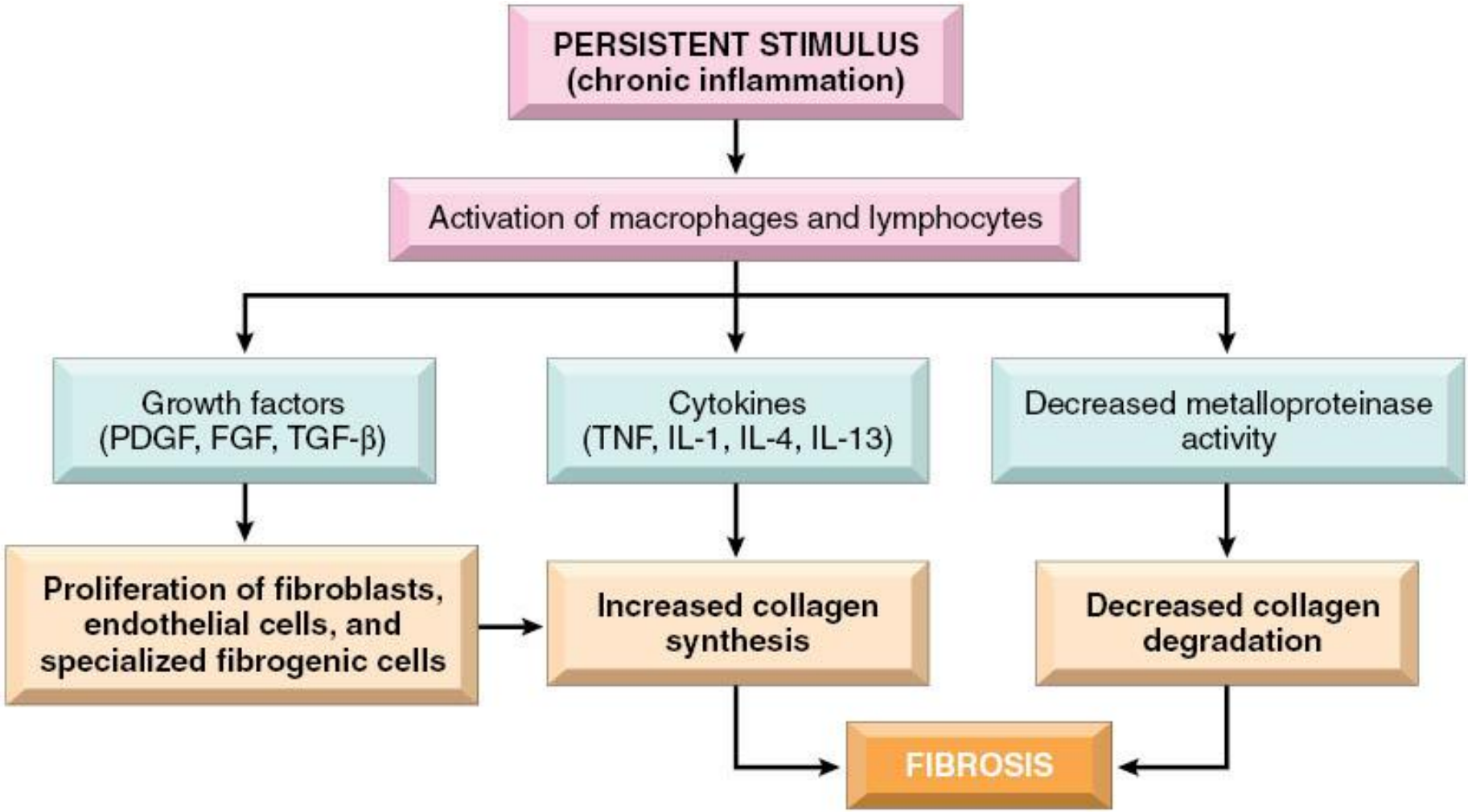

Copyright © 2010 by Saunders, an imprint of Elsevier Inc.